

The Outcomes of Treating Femoral Neck Fractures Using Bipolar Hemiarthroplasty

Adel Ebrahimpour,¹ Reza Zandi,¹ Maryam Ayazi,^{1,*} and Farshad Safdari²

¹Taleghani Hospital, Shahid Beheshti University of Medical Sciences, Tehran, IR Iran

²Bone Joint and Related Tissue Research Center, Shahid Beheshti University of Medical Sciences, Tehran, IR Iran

*Corresponding author: Maryam Ayazi, Taleghani Hospital, Shahid Beheshti University of Medical Sciences, Tehran, IR Iran. Tel: +98-9125505663, Fax: +98-2122608246, E-mail: marie.ayazi@yahoo.com

Received 2015 January 09; Revised 2015 March 14; Accepted 2015 April 06.

Abstract

Background: Femoral neck fractures (FNF) are a challenging orthopedic problem, and their appropriate treatment remains controversial. Nowadays, bipolar hemiarthroplasty (BHA) is increasingly used to treat FNF.

Objectives: In the current retrospective study, we investigated the outcomes of treating FNF with BHA.

Methods: There were 55 patients with FNF enrolled in the current retrospective study. The variables measured were mortality in the first postoperative year, returning to the pre-injury activity level, the Harris hip score (HHS) and pain intensity based on a visual analogue scale (VAS) at the last visit. The correlation between a delay in surgery, and mortality and HHS were investigated.

Results: Sixteen patients died within the first postoperative year (29%). HHS and VAS averaged 83.5 ± 15.5 and 0.7 ± 0.9 , respectively. Patients who achieved good or excellent outcomes were 72% and 74% returned to their previous activity level. Of the study group, 95% of patients ambulated with or without using assistive devices. Although we found no significant correlation between delay in surgery, and mortality or HHS, HHS decreased with increased time interval between injury and surgery.

Conclusions: The rate of mortality in the first postoperative year was high; however, functional outcomes were satisfactory. Most of the patients could return to their previous activity levels. In the current study, we found no significant correlation between delay in surgery, and mortality at the first postoperative year and HHS.

Keywords: Femoral Neck Fracture, Bipolar Hemiarthroplasty, Mortality, Pain, Functional Outcomes

1. Background

Hip fractures, including femoral neck fractures (FNF), are one of the most common injuries among the aging population and are associated with considerable financial burden on the healthcare system (1-3). Although recent studies have shown that the incidence of hip fractures in Iran and the related financial burden are lower compared to developed countries (4, 5), the figures are a reminder of the necessity of these devastating injuries. The figures for falling down and subsequent hip fractures have been reported as 237.1 and 93.6 per 100,000 person-years, respectively, for the population aged over 50 years (6). The cost of treating hip fractures in Iran accounts for 0.85% and 12.4% of the global and Middle East burden, respectively (7). The problem is more extensive and worrying in developed countries (1, 7). The aging of the population is associated with increased incidence of hip fractures (8-11).

Few patients with hip fracture can return to their pre-injury activity level and regain independence in activities of daily living (ADL) (12, 13). Half of hip fracture patients are dependent in ADL and nearly 25% require long-term care and treatment (14). Due to the particular circulatory system feeding the femoral head and neck, and the sophisticated anatomical, functional and biomechanical charac-

teristics, treatment of FNF remains challenging. Considering the increased life expectancy and complications following FNF, finding a safe and efficient treatment method for these fractures is necessary. There are several treatment options suggested for FNF including fixation using a cannulated screw, unipolar hemiarthroplasty (UHA), bipolar hemiarthroplasty (BHA) and total hip arthroplasty (THA); each with its advantages and disadvantages (2, 15-22).

The purpose of treating FNF differs in youth and elders. Although internal fixation and femoral head preservation are believed to be the preferred treatment goals (16), there is no consensus regarding the most appropriate modality of treatment. These controversies about the best treatment for FNF are more prominent in older patients with shorter life expectancy and lower functional demands. Many authors believe that the treatment must be selected individually based on the fracture pattern, displacement, pre-injury activity level, mental status of the patient, the quality of the bone and joint, the amount of independence of the patient in ADL and their general health status (16, 23-29).

2. Objectives

In the current retrospective study, we investigated the outcomes of treating FNF using BHA.

3. Methods

Between 2010 and 2012, 67 patients with displaced FNF (based on Garden's classification) underwent cementless BHA through a lateral surgical approach in Taleghani Hospital, Tehran, Iran. After the operation, these patients received daily subcutaneous low molecular-weight heparin (Clexane 40 - 60mg. based on body weight) for thromboprophylaxis for five weeks. Before the injury, all of the patients were ambulatory and independent in their ADL. Age, sex, mechanism of injury, underlying diseases, the time interval between injury and operation, development of infection, symptomatic deep venous thrombosis (DVT) or any other complications were determined using medical records. Patients were called and asked to undergo an evaluation if they were interested in participating in the study. Patients returning for the last evaluation signed an informed consent.

At the final visit, a Harris Hip Score (HHS) questionnaire was completed for all of the patients. The scores < 70 were graded as poor, between 70 - 79 as fair, between 80 - 89 as good and ≥ 90 as excellent. The pain intensity was determined utilizing a 10cm scale (visual analogue scale). In this scale, 0 indicated no pain and 10 indicated the most imaginable severe pain. Also, patients were asked about returning to their preoperative activity level. The mortality events at the first postoperative year were also recorded.

The correlation between delayed surgery, and the risk of first postoperative year mortality and functional outcomes was investigated utilizing Spearman's rank correlation coefficient (ρ) and Pearson's correlation coefficient (r), respectively. Statistical analysis was performed with SPSS statistical software (version 15.0; SPSS, Chicago, IL). A value of $P < 0.05$ was considered statistically significant.

4. Results

Of 67 patients, nine patients were lost due to change of address or unwillingness to cooperate in the study. Also, three patients died after the first postoperative day and were excluded. Fifty-five patients completed the study. The characteristics of the patients are presented in Table 1. Some patients suffered from more than one comorbidity.

Sixteen patients (29%) died at the first postoperative year (all-cause mortality). Thromboembolic disease was observed in one patient two weeks postoperatively, who died because of pulmonary embolism. One other patient

Table 1. The Characteristics of Patients with Femoral Neck Fracture Who Underwent Bipolar Hemiarthroplasty

Characteristics of Patients	Values
No. Patients	55
Age, y	72.9 \pm 14.3, 35 - 91
Gender	
Male	24
Female	31
Mechanism of injury	
Falling down	39
Direct trauma	5
Car accident	11
Side of fractured limb	
Right	37
Left	18
Comorbidity	
Without comorbidity	17
Hypertension	28
Ischemic heart disease	13
Malignancy	4
Asthma	2
Cerebrovascular accident	2
Diabetes mellitus	25
Hyperlipidemia	11
Others	13
Time interval between injury and surgery, d	7.1 \pm 3.8, 1 - 24

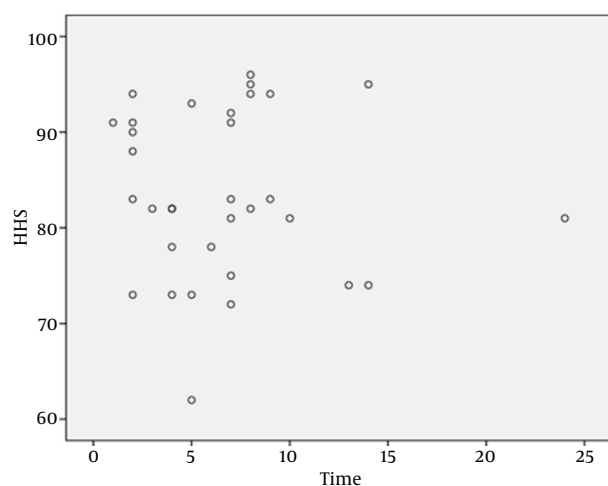
died intraoperatively because of myocardial infarction. Of the 39 remaining patients, two patients developed surgical site infection. One of them was treated successfully with oral antibiotic therapy, while another patient underwent irrigation and debridement several times. Prosthetic hip dislocation occurred in one patient, who underwent reoperation. The clinical and functional evaluations were performed for the 39 remaining patients (Table 2). These patients were followed for 28.1 \pm 3.8 months (range: 21 - 40 month).

The interval between injury and surgery was not correlated significantly with first year mortality ($P = 0.321$) and HHS ($P = 0.793$). However, Figure 1 shows that a decreased interval between injury and surgery is associated with increased HHS.

Table 2. The Clinical and Functional Outcomes of Patients with Femoral Neck Fracture Who Underwent Bipolar Hemiarthroplasty

Characteristics of Patients	Values
No. Patients	39
HHS	83.5 ± 15.5, (62 - 96)
Grading based on HHS	
Poor	3
Fair	8
Good	15
Excellent	13
Pain based on VAS	0.7 ± 0.9 (0 - 6)
Return to previous activity level	29
Current level of activity	
Bed rest	2
Ambulatory	24
Ambulatory with assistive devices	13

Abbreviations: HHS, Harris Hip Score; VAS, Visual Analogue Scale.

**Figure 1.** The Correlation of HHS and Interval Between Injury and Surgery

5. Discussion

Hip fractures are one of the most important and challenging orthopedic injuries. Several treatment modalities have been used for treating these injuries. However, bipolar hemiarthroplasty (BHA) is increasingly used worldwide to treat displaced femoral neck fractures (FNFs). Although, there have been several studies conducted regarding the results of the procedure, concerns about the rate of morbidity and mortality following FNF, especially in older patients with comorbidities, propelled us to perform the cur-

rent retrospective study.

Altay et al. retrospectively investigated the outcomes of cemented BHA in 76 patients over the age of 65 years. Patients were followed for at least one year. They found that HHS averaged 84.7 and 85.5 in patients operated on through posterior and anterior approaches, respectively. Although early dislocation occurred in 9.6% of patients who underwent the posterior approach, they concluded that BHA is an appropriate and effective treatment for this patient population and the approach does not affect the outcomes (30). In another study with 3.5 years follow up, Bezwada et al. evaluated the clinical and radiographic outcomes of cementless BHA for treating displaced FNF in patients over 65 years of age. The HHS averaged 82 points. Loosening of the femoral stem was found in two cases. Conversion to total hip arthroplasty (THA) was performed for six cases due to the severe groin pain. Bezwada et al. concluded that cementless BHA is a safe and efficient treatment modality with predictable outcomes (31). Rajak et al. treated 30 patients with displaced FNF using BHA and found acceptable short-term functional outcomes. One patient with intraoperative periprosthetic fracture and one with prosthetic dislocation were observed (32). Also, Unger et al. reported satisfactory outcomes of treating FNF using BHA with a low rate of complications (33). In 2013, van den Bekerom et al. reported the outcomes of hemiarthroplasty in patients with FNF. The surgeries were performed between 1975 - 89 and patients were followed up with until death. The authors found that the mortality rate after the first and fifth postoperative years was 28% and 63%, respectively. Sixteen percent of the patients underwent revision surgery due to aseptic loosening, protrusion or both (34). Schnependahl demonstrated that BHA is associated with increased mortality. However, the impact of BHA has significantly decreased over the last twenty years (35).

Utilizing bone cement in BHA has remained controversial. Recently, Langslet et al. found that both cemented and cementless BHAs are useful for treatment of displaced femoral neck fracture with satisfactory functional outcomes. Although, uncemented BHA was associated with a higher HHS, and the risk of later femoral fracture was greater in this group (36). Also, in a similar study, Ng and Krishna demonstrated that functional outcomes, complications and mortality were the same between cemented and cementless BHA (37). In addition, Figved et al. found that both arthroplasties can be used with good results for treating displaced FNF (38). A systematic review by Ahn et al. resulted in similar findings (18). These studies show that cemented or uncemented BHA are appropriate and reasonable treatment modalities for FNF in elderly patients and use of bone cement does not significantly affect the outcomes.

In the current study, we also evaluated the short-term outcomes of treating displaced FNFs in elderly patients (mean age: 73 years); most of them suffered from comorbidities. Unfortunately, 29% of our patients died during the first postoperative year. One patient died intraoperatively due to the myocardial infarction. In addition, despite chemical thromboprophylaxis, another patient died due to a pulmonary embolism. Of the surviving patients, one patient required reoperation because of dislocation, which was caused by a surgical technical error (excessive anteversion). We operated on a 35-year-old patient who suffered from malignancy and other comorbidities, and because of a short life expectancy, we decided not to perform open reduction and internal fixation for this patient. Deep infection and osteomyelitis developed in one patient who was treated successfully with antibiotic therapy and surgical debridement. There were no major complications in other patients. The mean of the HHS was acceptable (83.5) and 72% of patients achieved good to excellent outcomes. Most of the patients did not require analgesic consumption at the last visit. Only one patient complained of severe, bothersome pain. Interestingly, 74% of patients regained their pre-injury level of activity. Of 39 patients who were evaluated at the last visit, only two patients were on bed rest (5%), while the others could ambulate independently with or without using assistive devices.

Comparing the outcomes of hemiarthroplasty using bipolar and unipolar prostheses shows that although there are some advantages with using BHA, UHA can share many of these advantages with a lower cost (39-41). Stoffel et al. recommended using UHA for inactive elderly patients with FNF (39). In a recent meta-analysis by Liu et al., UHA and BHA achieved similar clinical outcomes in treatment of displaced FNF fractures in elderly patients (41). However, some authors prefer using BHA for this patient population (42).

Addressing the controversies about the most appropriate treatment modality for FNF, some surgeons compared the outcomes of internal fixation osteosynthesis and arthroplasty. A meta-analysis in 2003 found that arthroplasty is associated with reduced risk of revision surgery but with greater rate of infection, blood loss, operation time and possibly increased mortality rates, which should be evaluated in future studies with a greater sample size (43). In a meta-analysis by Dai et al., arthroplasty significantly reduced the rate of surgical revision and complications compared to internal fixation. They found no increased rate of mortality because of arthroplasty. Dai et al. suggested that arthroplasty should be considered as the primary treatment modality for elderly patients with FNF (2). Nicolaides et al. demonstrated that although arthroplasty has led to better functional outcomes and

lower rates of reoperation, the risk of infection, the volume of blood loss and the operation time were significantly higher with arthroplasty (44). Wang et al. found similar outcomes (20). Recently Stoen et al. reported the findings of a clinical trial and found no difference in terms of survival, complications and functional outcomes between hemiarthroplasty and internal fixation with two cannulated screws. However, they concluded that hemiarthroplasty is the treatment of choice with predictable outcomes for FNF. They advised more studies should be performed to compare THA and hemiarthroplasty (45). It seems that although some authors supported arthroplasty for treatment of FNF, each of the two methods (arthroplasty or internal fixation) has its own advantages and disadvantages, and more extensive studies are required.

Some authors compared the outcomes of hemiarthroplasty and THA for treating unstable FNF in elderly patients. For example, in a randomized clinical trial Blomfeldt et al. compared THA and BHA for treating displaced FNF in elderly patients and concluded that based on the better functional outcomes and the same rate of complications and mortality, THA can be used as the primary treatment (46). These findings were confirmed in other studies by Park et al. (47) and Hedbeck et al. (48). To our knowledge, there has been no study in which the superiority of BHA over THA has been shown, however, it seems that more studies are required.

Although there are several factors causing confusion in the choice of a preferred treatment method for FNF in elderly patients (several treatment modalities, multiple factors affecting the outcomes of surgery and different methods in designing the studies), BHA seems to be a safe and efficient method with satisfactory clinical, functional and radiological outcomes. However, the high rate of mortality at the first postoperative year is a reminder that the low-risk patients must be carefully selected preoperatively based on diagnostic and screening tests.

In the current study, we found no significant correlation between delayed surgery, and functional outcomes and mortality at the first postoperative year. However, our findings suggest that the HHS was higher in patients operated on with less delay. It seems that our patients underwent surgery with a considerable operational delay compared to current guidelines. However, one should note that some problems, such as comorbidities (cardiovascular/pulmonary diseases) in elderly patients, require more detailed preoperative assessment, which is, unfortunately, a time consuming process in governmental hospitals.

Verbeek et al. reported similar results to our study in a retrospective study on 192 hip fractures. They found that delayed surgery did not affect the risk of mortality at the first postoperative year but can increase the risk of infec-

tion (49).

Similar to other studies, there were some limitations with our study. The most important limitation of the current study was its retrospective nature. We investigated the short-term outcomes and additional long-term follow up seems to be required.

In conclusion, the first year mortality in treating elderly patients with displaced FNF using cementless BHA was considerable, however, the functional outcomes were satisfactory in surviving patients. Seventy-four percent of their patients returned to their pre-injury activities. Most of the patients were ambulatory with and without using assistive devices. The interval between injury and surgery was not correlated with mortality and functional outcomes.

Footnote

Authors' Contribution: Study concept and design: Adel Ebrahimpour; acquisition of data: Maryam Ayazi; analysis and interpretation of data: Farshad Safdari; drafting of the manuscript: Maryam Ayazi; critical revision of the manuscript for important intellectual content: Reza Zandi; statistical analysis: Farshad Safdari; administrative, technical, and material support: Reza Zandi; study supervision: Adel Ebrahimpour.

References

- Johnell O, Gullberg B, Allander E, Kanis JA, Medos Study Group. The apparent incidence of hip fracture in Europe: a study of national register sources. *Osteoporos Int*. 1992;**2**(6):298-302. [PubMed: 1421798].
- Dai Z, Li Y, Jiang D. Meta-analysis comparing arthroplasty with internal fixation for displaced femoral neck fracture in the elderly. *J Surg Res*. 2011;**165**(1):68-74. doi: 10.1016/j.jss.2009.03.029. [PubMed: 19552922].
- Centers for Disease C. Fatalities and injuries from falls among older adults—United States, 1993-2003 and 2001-2005. *MMWR Morb Mortal Wkly Rep*. 2006;**55**(45):1221-4. [PubMed: 17108890].
- Moayyeri A, Soltani A, Larijani B, Naghavi M, Alaeddini F, Abolhassani F. Epidemiology of hip fracture in Iran: results from the Iranian Multi-center Study on Accidental Injuries. *Osteoporos Int*. 2006;**17**(8):1252-7. doi: 10.1007/s00198-006-0105-2. [PubMed: 16680499].
- Ahmadi-Abhari S, Moayyeri A, Abolhassani F. Burden of hip fracture in Iran. *Calcif Tissue Int*. 2007;**80**(3):147-53. doi: 10.1007/s00223-006-0242-9. [PubMed: 17340222].
- Abolhassani F, Moayyeri A, Naghavi M, Soltani A, Larijani B, Shalmani HT. Incidence and characteristics of falls leading to hip fracture in Iranian population. *Bone*. 2006;**39**(2):408-13. doi: 10.1016/j.bone.2006.01.144. [PubMed: 16510325].
- Royal College of Physicians of London. Fractured neck of femur: prevention management. London: Royal College of Physicians of London; 1989.
- Chang Q, Liu S, Guan C, Yu F, Wu S, Jiang C. Bipolar hip arthroplasty. *J Arthroplasty*. 2011;**26**(8):1455-9. doi: 10.1016/j.arth.2011.03.003. [PubMed: 21530148].
- Walter LC, Lui LY, Eng C, Covinsky KE. Risk of hip fracture in disabled community-living older adults. *J Am Geriatr Soc*. 2003;**51**(1):50-5. [PubMed: 12534845].
- Zuckerman JD. Hip fracture. *N Engl J Med*. 1996;**334**(23):1519-25. doi: 10.1056/NEJM199606063342307. [PubMed: 8618608].
- Evans PJ, McGrory BJ. Fractures of the proximal femur. *Hospital Physician*. 2002;**38**(4):30-8.
- van Balen R, Steyerberg EW, Polder JJ, Ribbers TL, Habbema JD, Cools HJ. Hip fracture in elderly patients: outcomes for function, quality of life, and type of residence. *Clin Orthop Relat Res*. 2001(390):232-43. [PubMed: 11550871].
- DerSimonian R, Laird N. Meta-analysis in clinical trials. *Control Clin Trials*. 1986;**7**(3):177-88. [PubMed: 3802833].
- Haentjens P, Autier P, Barette M, Boonen S, Belgian Hip Fracture Study G. Predictors of functional outcome following intracapsular hip fracture in elderly women. A one-year prospective cohort study. *Injury*. 2005;**36**(7):842-50. doi: 10.1016/j.injury.2005.02.002. [PubMed: 15949486].
- Krastman P, van den Bent RP, Krijnen P, Schipper IB. Two cannulated hip screws for femoral neck fractures: treatment of choice or asking for trouble?. *Arch Orthop Trauma Surg*. 2006;**126**(5):297-303. doi: 10.1007/s00402-006-0143-4. [PubMed: 16628427].
- Sendtner E, Renkawitz T, Kramny P, Wenzl M, Grifka J. Fractured neck of femur—internal fixation versus arthroplasty. *Dtsch Arztebl Int*. 2010;**107**(23):401-7. doi: 10.3238/arztebl.2010.0401. [PubMed: 20589205].
- Seyfettinoglu F, Ersan O, Kovalak E, Duygun F, Ozsar B, Ates Y. Fixation of femoral neck fractures with three screws: results and complications. *Acta Orthop Traumatol Turc*. 2011;**45**(1):6-13. doi: 10.3944/AOTT.2011.2434. [PubMed: 21478657].
- Ahn J, Man LX, Park S, Sodl JF, Esterhai JL. Systematic review of cemented and uncemented hemiarthroplasty outcomes for femoral neck fractures. *Clin Orthop Relat Res*. 2008;**466**(10):2513-8. doi: 10.1007/s11999-008-0368-3. [PubMed: 18651200].
- Zhang Y, Tian L, Yan Y, Sang H, Ma Z, Jie Q, et al. Biomechanical evaluation of the expansive cannulated screw for fixation of femoral neck fractures. *Injury*. 2011;**42**(11):1372-6. doi: 10.1016/j.injury.2011.07.004. [PubMed: 21824615].
- Wang J, Jiang B, Marshall RJ, Zhang P. Arthroplasty or internal fixation for displaced femoral neck fractures: which is the optimal alternative for elderly patients? A meta-analysis. *Int Orthop*. 2009;**33**(5):1179-87. doi: 10.1007/s00264-009-0763-8. [PubMed: 19343344].
- Rogmark C, Flensburg L, Fredin H. Undisplaced femoral neck fractures—no problems? A consecutive study of 224 patients treated with internal fixation. *Injury*. 2009;**40**(3):274-6. doi: 10.1016/j.injury.2008.05.023. [PubMed: 19070851].
- Enocson A, Hedbeck CJ, Tornkvist H, Tidermark J, Lapidus LJ. Unipolar versus bipolar Exeter hip hemiarthroplasty: a prospective cohort study on 830 consecutive hips in patients with femoral neck fractures. *Int Orthop*. 2012;**36**(4):711-7. doi: 10.1007/s00264-011-1326-3. [PubMed: 21789497].
- Ly TV, Swiontkowski MF. Management of femoral neck fractures in young adults. *Indian J Orthop*. 2008;**42**(1):3-12. doi: 10.4103/0019-5413.38574. [PubMed: 19823648].
- Miller CW. Survival and ambulation following hip fracture. *J Bone Joint Surg Am*. 1978;**60**(7):930-4. [PubMed: 701341].
- Shah AK, Eissler J, Radomislki T. Algorithms for the treatment of femoral neck fractures. *Clin Orthop Relat Res*. 2002(399):28-34. [PubMed: 12011691].
- Bhattacharyya T, Iorio R, Healy WL. Rate of and risk factors for acute inpatient mortality after orthopaedic surgery. *J Bone Joint Surg Am*. 2002;**84-A**(4):562-72. [PubMed: 11940616].
- Center JR, Nguyen TV, Schneider D, Sambrook PN, Eisman JA. Mortality after all major types of osteoporotic fracture in men and women: an observational study. *Lancet*. 1999;**353**(9156):878-82. doi: 10.1016/S0140-6736(98)09075-8. [PubMed: 10093980].

28. Hamlet WP, Lieberman JR, Freedman EL, Dorey FJ, Fletcher A, Johnson EE. Influence of health status and the timing of surgery on mortality in hip fracture patients. *Am J Orthop (Belle Mead NJ)*. 1997;**26**(9):621-7. [PubMed: [9316725](#)].
29. Macaulay W, Nellans KW, Iorio R, Garvin KL, Healy WL, Rosenwasser MP, et al. Total hip arthroplasty is less painful at 12 months compared with hemiarthroplasty in treatment of displaced femoral neck fracture. *HSS J*. 2008;**4**(1):48-54. doi: [10.1007/s11420-007-9061-4](#). [PubMed: [18751862](#)].
30. Altay MA, Erturk C, Isikan UE. [Bipolar hemiarthroplasty for the treatment of femoral neck fractures and the effect of surgical approach on functional results]. *Ekleml Hastalik Cerrahisi*. 2010;**21**(3):136-41. [PubMed: [21067494](#)].
31. Bezwada HP, Shah AR, Harding SH, Baker J, Johanson NA, Mont MA. Cementless bipolar hemiarthroplasty for displaced femoral neck fractures in the elderly. *J Arthroplasty*. 2004;**19**(7 Suppl 2):73-7. [PubMed: [15457422](#)].
32. Rajak MK, Jha R, Kumar P, Thakur R. Bipolar hemiarthroplasty for intracapsular femoral neck fractures in elderly patients. *J Orthop Surg (Hong Kong)*. 2013;**21**(3):313-6. [PubMed: [24366791](#)].
33. Unger AC, Dirksen B, Renken FG, Wilde E, Willkomm M, Schulz AP. Treatment of femoral neck fracture with a minimal invasive surgical approach for hemiarthroplasty - clinical and radiological results in 180 geriatric patients. *Open Orthop J*. 2014;**8**:225-31. doi: [10.2174/1874325001408010225](#). [PubMed: [25136389](#)].
34. van den Bekerom MP, Sierevelt IN, Bonke H, Raaymakers EL. The natural history of the hemiarthroplasty for displaced intracapsular femoral neck fractures. *Acta Orthop*. 2013;**84**(6):555-60. doi: [10.3109/17453674.2013.867763](#). [PubMed: [24286565](#)].
35. Schneppendahl J, Grassmann JP, Petrov V, Bottner F, Korbl B, Hakimi M, et al. Decreasing mortality after femoral neck fracture treated with bipolar hemiarthroplasty during the last twenty years. *Int Orthop*. 2012;**36**(10):2021-6. doi: [10.1007/s00264-012-1600-z](#). [PubMed: [22740187](#)].
36. Langslet E, Frihagen F, Opland V, Madsen JE, Nordsletten L, Figved W. Cemented versus uncemented hemiarthroplasty for displaced femoral neck fractures: 5-year followup of a randomized trial. *Clin Orthop Relat Res*. 2014;**472**(4):1291-9. doi: [10.1007/s11999-013-3308-9](#). [PubMed: [24081667](#)].
37. Ng ZD, Krishna L. Cemented versus cementless hemiarthroplasty for femoral neck fractures in the elderly. *J Orthop Surg (Hong Kong)*. 2014;**22**(2):186-9. [PubMed: [25163952](#)].
38. Figved W, Opland V, Frihagen F, Jervidal T, Madsen JE, Nordsletten L. Cemented versus uncemented hemiarthroplasty for displaced femoral neck fractures. *Clin Orthop Relat Res*. 2009;**467**(9):2426-35. doi: [10.1007/s11999-008-0672-y](#). [PubMed: [19130162](#)].
39. Stoffel KK, Nivbrant B, Headford J, Nicholls RL, Yates PJ. Does a bipolar hemiprostheses offer advantages for elderly patients with neck of femur fracture? A clinical trial with 261 patients. *ANZ J Surg*. 2013;**83**(4):249-54. doi: [10.1111/ans.12048](#). [PubMed: [23320780](#)].
40. Ayhan E, Kesmezacar H, Karaman O, Sahin A, Kir N. Bipolar or unipolar hemiarthroplasty after femoral neck fracture in the geriatric population. *Balkan Med J*. 2013;**30**(4):400-5. doi: [10.5152/balkanmedj.2013.8571](#). [PubMed: [25207148](#)].
41. Liu Y, Tao X, Wang P, Zhang Z, Zhang W, Qi Q. Meta-analysis of randomised controlled trials comparing unipolar with bipolar hemiarthroplasty for displaced femoral-neck fractures. *Int Orthop*. 2014;**38**(8):1691-6. doi: [10.1007/s00264-014-2355-5](#). [PubMed: [24817022](#)].
42. Inngul C, Hedbeck CJ, Blomfeldt R, Lapidus G, Ponzer S, Enocson A. Unipolar hemiarthroplasty versus bipolar hemiarthroplasty in patients with displaced femoral neck fractures: a four-year follow-up of a randomised controlled trial. *Int Orthop*. 2013;**37**(12):2457-64. doi: [10.1007/s00264-013-2117-9](#). [PubMed: [24122045](#)].
43. Bhandari M, Devereaux PJ, Swiontkowski MF, Tornetta P3, Obreskley W, Koval KJ, et al. Internal fixation compared with arthroplasty for displaced fractures of the femoral neck. A meta-analysis. *J Bone Joint Surg Am*. 2003;**85-A**(9):1673-81. [PubMed: [12954824](#)].
44. Nicolaides V, Galanakis S, Mavrogenis AF, Sakellariou VI, Papakostas I, Nikolopoulos CE, et al. Arthroplasty versus internal fixation for femoral neck fractures in the elderly. *Strategies Trauma Limb Reconstr*. 2011;**6**(1):7-12. doi: [10.1007/s11751-010-0099-3](#). [PubMed: [21589676](#)].
45. Stoen RO, Lofthus CM, Nordsletten L, Madsen JE, Frihagen F. Randomized trial of hemiarthroplasty versus internal fixation for femoral neck fractures: no differences at 6 years. *Clin Orthop Relat Res*. 2014;**472**(1):360-7. doi: [10.1007/s11999-013-3245-7](#). [PubMed: [23975250](#)].
46. Blomfeldt R, Tornkvist H, Eriksson K, Soderqvist A, Ponzer S, Tidermark J. A randomised controlled trial comparing bipolar hemiarthroplasty with total hip replacement for displaced intracapsular fractures of the femoral neck in elderly patients. *J Bone Joint Surg Br*. 2007;**89**(2):160-5. doi: [10.1302/0301-620X.89B2.18576](#). [PubMed: [17322427](#)].
47. Park KS, Oh CS, Yoon TR. Comparison of Minimally Invasive Total Hip Arthroplasty versus Conventional Hemiarthroplasty for Displaced Femoral Neck Fractures in Active Elderly Patients. *Chonnam Med J*. 2013;**49**(2):81-6. doi: [10.4068/cmj.2013.49.2.81](#). [PubMed: [24010071](#)].
48. Hedbeck CJ, Enocson A, Lapidus G, Blomfeldt R, Tornkvist H, Ponzer S, et al. Comparison of bipolar hemiarthroplasty with total hip arthroplasty for displaced femoral neck fractures: a concise four-year follow-up of a randomized trial. *J Bone Joint Surg Am*. 2011;**93**(5):445-50. doi: [10.2106/JBJS.00474](#). [PubMed: [21368076](#)].
49. Verbeek DO, Ponsen KJ, Goslings JC, Heetveld MJ. Effect of surgical delay on outcome in hip fracture patients: a retrospective multivariate analysis of 192 patients. *Int Orthop*. 2008;**32**(1):13-8. doi: [10.1007/s00264-006-0290-9](#). [PubMed: [17219213](#)].